

Classic and Follicular Variant of Papillary Thyroid Microcarcinoma: 2 Different Phenotypes Beyond Tumor Size

Clotilde Sparano,¹  Mario Rotondi,²  Valentina Verdiani,¹ Paolo Brunori,³ Francesca Castiglione,⁴ Caterina Bartoli,⁴ Giuliano Perigli,⁵ Benedetta Badii,⁵ Vania Vezzosi,⁴ Gabriele Simontacchi,⁶ Lorenzo Livi,⁷ Lorenzo Antonuzzo,⁸ Mario Maggi,¹ and Luisa Petrone⁹ 

¹Endocrinology Unit, Department of Experimental and Clinical Biomedical Sciences ‘Mario Serio’, University of Florence, Florence, Italy

²Istituti Clinici Scientifici Maugeri IRCCS, Unit of Internal Medicine and Endocrinology, Department of Internal Medicine and Therapeutics, University of Pavia, Pavia, Italy

³International Inequality Institute, London School of Economics, London, UK

⁴Department of Histopathology and Molecular Diagnostics, Careggi Hospital, Florence, Italy

⁵Unit of General and Endocrine Surgery, Centre of Oncological and Minimally Invasive Surgery, Department of Surgery and Translational Medicine, University of Florence, Florence, Italy

⁶Radiation Oncology Unit, Careggi Hospital, Florence, Italy

⁷Radiation Oncology Unit, Department of Biomedical, Experimental and Clinical Sciences ‘Mario Serio’, University of Florence, Florence, Italy

⁸Clinical Oncology Unit, Department of Experimental and Clinical Medicine, University of Florence, Florence, Italy

⁹Endocrinology Unit, Medical-Geriatric Department, Careggi Hospital, Florence, Italy

Correspondence: Luisa Petrone, MD, PhD, Endocrinology Unit, Medical-Geriatric Department, Azienda Ospedaliero-Universitaria, Careggi, Viale Pieraccini 18, 50139 Florence, Italy. Email: luisa.petrone@unifi.it.

Abstract

Context: Despite the wide revision of current guidelines, the management of papillary thyroid microcarcinoma (mPTC) still has to be decided case by case. There is conflicting evidence about the role of more frequent histological subtypes, and no data about potential differences at presentation.

Objective: Our aim was to compare the phenotype of the 2 most frequent mPTC variants, namely, classical papillary thyroid microcarcinoma (mPTCc) and the follicular variant of papillary thyroid microcarcinoma (mFVPTC).

Methods: Retrospective observational study, from January 2008 to December 2017 of a consecutive series of patients with mPTCc and mFVPTC. All cases were classified according to the 2015 American Thyroid Association (ATA) risk classification. Clinical and preclinical features of mPTCc and mFVPTC at diagnosis were collected. The comparison was also performed according to the incidental/nonincidental diagnosis and differences were verified by binary logistic analysis.

Results: In total, 235 patients were eligible for the analysis (125 and 110 mPTCc and mFVPTC, respectively). Compared with mPTCc, mFVPTCs were more often incidental and significantly smaller (4 vs 7 mm) ($P < .001$ all), possibly influenced by the higher rate of incidental detection. mFVPTC and incidental ($P < .001$ both) tumors were significantly more often allocated within the low-risk class. A logistic regression model, with ATA risk class as the dependent variable, showed that both mFVPTC (OR 0.465 [0.235–0.922]; $P = .028$) and incidental diagnosis (OR 0.074 [0.036–0.163]; $P < .001$) independently predicted ATA risk stratification.

Conclusion: mFVPTC shows some differences in diagnostic presentation compared with mPTCc, and seems to retain a significant number of favorable features, including a prevalent onset as incidental diagnosis.

Key Words: papillary thyroid microcarcinoma, thyroid neoplasms, phenotype, risk assessment

Abbreviations: AACE/ACE-AME, American Association of Clinical Endocrinologists; ATA, American Thyroid Association; AUC, area under the curve; mDTC, differentiated thyroid microcarcinoma; mPTC, papillary thyroid microcarcinoma; mPTCc, classical papillary thyroid microcarcinoma; mFVPTC, follicular variant of papillary thyroid microcarcinoma; ROC, receiver operating characteristic; TSH, thyrotropin; TIRADS, Thyroid Imaging Reporting and Data Systems; US, ultrasonographic.

The management of differentiated thyroid microcarcinoma (mDTC) encompasses different therapeutic options, including active surveillance, since these tumors show a subcentimetric size and, in most cases, quite indolent behavior. Due to previous improper diagnostic campaigns on thyroid nodules, we

have witnessed an diagnosis of epidemic proportions of these small cancers, especially papillary thyroid microcarcinoma (mPTC) [1, 2], without, however, any relevant increase in morbidity or mortality [1, 3]. Furthermore, a number of mPTCs have been found after thyroidectomy performed for

benign conditions. The so-called “thyroid incidentalomas” show a harmless course and seem to represent a distinctive category of mPTC [4].

Thus, mPTC has been thoroughly investigated in order to reduce its overdiagnosis and treatment [2], given that this would not affect patient prognosis [1, 3]. Based on the above concepts, extensive revision of the current guidelines has been performed, assigning eligible mPTCs to less aggressive therapeutic approaches, such as lobectomy [2], locoregional treatments [5], or active surveillance [6]. However, the efforts to streamline mPTC management still face several clinical constraints. For instance, the presence of multifocal tumor foci increases the risk of a contralateral recurrence, reducing the effectiveness of lobectomy [7]. Mini-invasive approaches are indeed promising, but have been investigated in small and heterogeneous surveys [5]. On the other hand, tumor active surveillance does not reduce management costs in long-term follow-up, and these protocols are often perceived with anxiety by patients, showing a high drop-out rate [6]. Finally, a small proportion of mPTCs have shown more virulent behavior, with extrathyroidal extension or locoregional involvement, since their earliest stages [8]. Therefore, we are still far from a universal and reliable indication on mPTC management. At present, some clinical features of mPTCs were suggested to be associated with more aggressive behavior. These latter include (1) microcarcinomas larger than 5 mm [8, 9]; (2) a subcapsular location within the upper portion of the gland [8, 9]; (3) the presence of metastasis to laterocervical lymph nodes [8, 9]; and (4) some less common histological variants of mPTC (ie, the tall cell variant) [2]. On the other hand, the role of other features remains controversial. For instance, the role of more indolent variants has been less investigated and the evidence from the literature is often conflicting, although some of these subtypes represent a large proportion of the histological diagnosis.

The aim of this retrospective study was to compare the phenotype at presentation of the classical mPTC (mPTCc)—the “reference” histotype—and the follicular variant of mPTC (mFVPTC)—the most frequent mPTC variant—in a large Italian cohort sample. As a second aim, the comparison was also performed according to the incidental or nonincidental (presurgery) diagnosis, in order to uncover possible clinical, histological, and molecular differences in the sample subsets.

Materials and Methods

This observational, retrospective study analyzed a consecutive series of mPTCs, from January 1, 2008, to December 31, 2017, that had been diagnosed and followed at the Endocrinology Unit of Florence Careggi Hospital. Inclusion criteria were (1) diagnosis of mPTC with maximal size ≤ 10 mm at histology, and only considering 2 variants: mPTCc and mFVPTC; (2) age ≥ 18 years old, who had provided a written informed consent; and (3) available clinical, histological, and follow-up data. Exclusion criteria were (1) histological diagnosis other than mPTC; (2) tumor size > 10 mm; and (3) lack of fundamental clinical or histological information.

For each patient, we collected several clinical features, namely, age, gender, familial history of thyroid cancer, concurrent autoimmune thyroid disease, history of other cancer, and presurgical thyrotropin (TSH) levels. For nonincidental cases, we collected all the ultrasonographic (US) features of the investigated nodules (including size [3-dimensional];

composition [solid, mixed, or cystic]; position of the solid portion in case of a mixed nodule [eccentric or not]; echogenicity [anechoic, hyperechoic, or isoechoic; slightly hypoechoic, hypoechoic, or marked hypoechoic]; halo [present, absent, or present but discontinuous or thick]; margins [well defined or smooth, irregular, or blurred]; shape [taller than wide], presence of echogenic foci [hyperechoic spot, macro- and microcalcifications]; rim calcification with extrusive soft tissue component and type of vascularization [absence of flow signals; perinodular and absent or slight intranodular blood flow; marked intranodular blood flow or mixed]) and we scored each lesion according to the 2 highest performing nodule US scores in our institution’s experience [10]: the American College of Radiology (ACR) Thyroid Imaging Reporting and Data Systems (TI-RADS) [11] and the American Association of Clinical Endocrinologists (AAACE/ACE-AME) [12], as previously reported [10]. Among the physicians, Cohen’s κ statistics ranged from 0.5 to 0.73, according to different US scores [10].

Thyroid cytology was classified according to the 2007 British Thyroid Association [13] until May 2014 and, thereafter, by applying the SIAPEC-IAP classification [14]. For ease, we adopted the label Tir3 for both Tir3A and Tir3B cytology.

Regarding the histological classification, each sample was analyzed according to 2010 and 2017 TNM VII and VIII [15, 16]. We collected all histological tumor features, including mDTC variants and other histological features, such as tumor sizes, multifocality, growth pattern (expansive or infiltrative), capsule characteristics (present/absent; complete/partial/incomplete), minimal extrathyroidal extension (mETE), and pathological lymph nodes (N1).

Incidental diagnosis of mPTC was made in cases of (1) occasional findings after surgery for nononcological purposes, or (2) tumor occasionally found and located outside the thyroid lesion/s considered during diagnostic procedures.

Available molecular tests (*BRAF-V600E* and *H-K-N-RAS* hot spot mutations) from histological samples were also collected. All the molecular analyses were performed from formalin-fixed paraffin-embedded whole tissue. Inconclusive molecular tests ($n = 12$) were defined as specimens not suitable for any molecular data processing, due to insufficient DNA concentration (< 0001 ng/ μ L, the sensitivity threshold for molecular test), after extraction or with extremely fragmented DNA after extraction, thus resulting in failure of polymerase chain reaction amplification and detection.

BRAF and *H-K-N-RAS* mutations were detected using the EasyPGX® ready THYROID kit (Diatech Pharmacogenetics, Ancona, Italy). All the analyses were performed using matrix-assisted laser desorption/ionization time of flight mass spectrometry method and by real-time polymerase chain reaction with marked system CE IVD EasyPGX® ready Thyroid. Our pathology laboratory is part of the European Molecular Genetics Quality Network for External Quality Assessment.

Clinical risk stratification has been performed according to the 2015 American Thyroid Association (ATA) guidelines at the end of diagnostic procedures [2].

In order to find potential differences, patients’ features were compared after stratifying the samples into 2 different populations, in other words according to the histological subtype and to the incidental or nonincidental diagnosis.

This study was approved by the local ethics committee (Comitato Etico Area Vasta Centro-CEAVC, Florence,

Table 1. Patients' characteristics and comparison between the 2 most frequent histotypes

	All cases n = 235	mPTCc n = 125	mFVPTC n = 110	P ^a
Male gender, n (%)	45 (19.1)	24 (19.2)	21 (19.1)	NS
Age, years	53.36 ± 14.38	49.48 ± 14.84	57.78 ± 12.51	<.001
History of autoimmune thyroid disease, ^b n (%)	71 (50.3)	43 (52.4)	28 (47.5)	NS
TSH at diagnosis, mU/L	1.41 (0.81-2.38)	1.71 (0.99-2.81)	1.12 (0.53-1.88)	.004
Familial history of DTC, n (%)	11 (4.9)	6 (5.0)	5 (4.8)	NS
History of other cancer, n (%)	25 (11.1)	12 (10.0)	13 (12.4)	NS
Tumour size, mm	5.76 ± 3.3	6.79 ± 2.9	4.58 ± 3.29	<.001
<i>BRAF-V600E</i> , n (%) ^c	69 (51.9)	50 (69.4)	19 (31.1)	<.001
<i>H-K-N-RAS</i> , n (%) ^c	17 (12.8)	3 (4.2)	14 (23.0)	.001
STAGE AJCC 2010, n (%)				
I for <45 years old	60 (25.5)	47 (37.6)	13 (11.8)	<.001
I for ≥ 45 years old	127 (54.0)	48 (38.4)	79 (71.8)	<.001
III for ≥ 45 years old	45 (19.1)	29 (23.2)	16 (14.5)	NS
IVA for ≥ 45 years old	3 (1.3)	1 (0.8)	2 (1.8)	NS
STAGE AJCC 2017, n (%)				
I for <55 years old	117 (49.8)	75 (60)	42 (38.2)	.001
I for ≥ 55 years old	111 (47.2)	47 (37.6)	64 (58.2)	.001
II for ≥ 55 years old	7 (3.0)	3 (2.4)	4 (3.6)	NS
Incidental tumor, n (%)	114 (48.5)	43 (34.4)	71 (64.5)	<.001
Not capsulated, n (%)	158 (69.0)	79 (65.3)	79 (73.1)	NS
Infiltrative growth pattern, n (%)	92 (41.4)	60 (51.3)	32 (30.5)	.001
Multifocality, n (%)	87 (37.3)	50 (40.3)	37 (33.9)	NS

Bold numbers refer to statistically significant differences.

Abbreviations: DTC, differentiated thyroid cancer; mFVPTC, follicular variant of papillary thyroid microcarcinoma; mPTCc, classical papillary thyroid microcarcinoma; NS, not significant; TSH thyrotropin.

^aP values have been calculated between mPTCc and mFVPTC subgroups.

^bConsidering Graves' disease (31% of positive cases) and Hashimoto thyroiditis (69% of positive cases) on a total evaluable sample of 141 cases;

^cConsidering that the final available analyses were conducted in 133 valid samples. See materials and methods for details.

Tuscany, Italy, ref. 20534) and conducted according to the Declaration of Helsinki.

Statistical Analysis

Continuous variables were expressed as mean ± SD when normally distributed and as median (quartiles) when non-normally distributed. Qualitative parameters were expressed as numbers and percentages. Differences between the 2 subgroups were analyzed using the t-test or Mann–Whitney test for continuous variables and chi-square test or Fisher–Yates test for dummy variables, according to sample size. ACR-TIRADS and AACE/ACE-AME accuracy were analyzed by receiver operating characteristic (ROC) curve analysis. Molecular results were summarized by an OncoPrint plot [17, 18]. The risk of being classified as low or intermediate ATA risk has been estimated, considering ATA risk as a dummy variable. All statistics were performed by SPSS for Windows 26.0 statistical software.

Results

Population Overview According to the Histological Variants

Among 277 thyroid microcarcinomas, mPTC histology was found in 235 cases. Of those, 125 and 110 were mPTCc and

mFVPTC, respectively, and, therefore, were eligible for this study. We excluded 42 cases showing other histology, including infrequent mDTC variants (10 oncocytic variants; 6 solid variants; 3 minimally invasive follicular; 2 occult sclerosing; 2 follicular with uncertain malignancy potential; 2 Hurtle cell carcinoma; 2 minimally invasive Hurtle cell carcinoma; 3 follicular thyroid cancer; 2 solid insular; 1 papillary carcinoma with dedifferentiated areas; 1 insular variant; 1 anaplastic thyroid cancer; 1 solid trabecular variant) and 6 medullary thyroid cancers. For 30 cases of other mDTCs, clinical and histological features at diagnosis were available. The clinical presentation of these subtypes comparing aggressive and non-aggressive histology are shown elsewhere (Table S1 [19]). Probably due to the small number of each tumor subtype, no differences were found, except for the ATA risk stratification. In fact, due to the higher recurrence risk provided by aggressive histology, in the absence of additional risk features, they were allocated to the intermediate-risk class ($P < .001$), according to international guidelines and literature evidence [2, 20].

Table 1 shows the main characteristics of the whole sample either overall or stratified according to the 2 major histological subtypes, namely mPTCc and mFVPTC.

Briefly, comparing the 2 aforementioned subtypes, we found some significant differences (Table 1). Notably, patients with mFVPTC were older (57.8 vs 49.5 years, $P < .001$), more

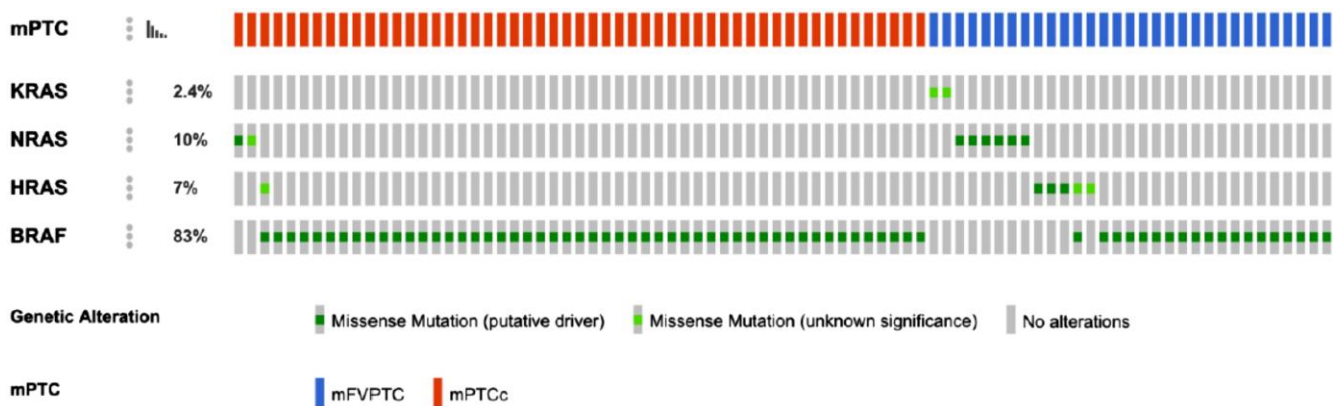


Figure 1. OncoPrint representation of positive genetic mutations. Graphic representation of positive molecular analyses, from 133 analyzed samples. For 84 patients a mutation in *BRAF-V600E* and/or *H-K-N-RAS* genes was found. In particular, 50 mPTCc and 19 mFVPTC showed a *BRAF-V600E* mutation and 3 mPTCc and 14 mFVPTC showed *H-K-N-RAS*. In 2 cases, 2 simultaneous mutations in *BRAF-V600E* and *H-RAS* were found. Negative or inconclusive results are not shown. Abbreviations: mPTC, papillary thyroid microcarcinoma; mPTCc, classical papillary thyroid microcarcinoma; mFVPTC, follicular variant of papillary thyroid microcarcinoma.

often they had an incidental diagnosis (71 vs 43 cases, $P < .001$), and showed lower levels of TSH at diagnosis ($P = .004$). mFVPTC showed a smaller mean size at histology (4.6 vs 6.8 mm, $P < .001$) than mPTCc, which is partially due to the higher proportion of incidental cases. Considering the stage, most of the cases were classified as stage I according to both VII [15] and VIII [16] AJCC TNM editions (Table 1). With respect to the other histological features, only the infiltrative growth pattern was more common in the mPTCc subgroup ($P = .001$).

A nonsignificant trend for a higher rate of locoregional involvement in the central compartment and lateral cervical lymph nodes at diagnosis was observed in mPTCc (data not shown).

Among the 235 potential tumor samples, only 145 cases (62%) were available for molecular testing; of them 133 (92%) were informative. *BRAF-V600E* mutation was more prevalent in mPTCc ($P < .001$), while a mutation in 1 of the *RAS* genes was more often found in mFVPTC ($P = .001$) (Table 1). Figure 1 provides an OncoPrint representation of positive molecular results [17, 18]. Considering the association between *BRAF-V600E* and lymph node metastasis, a trend to significance for mutated tumors ($P = .059$) was observed.

Clinical Presentation According to Incidental or Nonincidental Diagnosis

As shown in Table 2, similar prevalence of incidentalomas (114 out of 235; 48.5%) and nonincidentalomas (121 out of 235; 51.5%) was observed. However, the comparison of incidental and nonincidental mPTCs highlighted several differences in clinical, histological, and molecular features between the 2 groups (Table 2). Of note, incidental tumors were significantly more represented by mFVPTC (62%). Furthermore, as observed in mFVPTC, incidental tumors were characterized by smaller size ($P < .001$) and older age of patients (Tables 1 and 2).

Considering only nonincidental microcarcinomas, Table 3 shows differences between the 2 histological variants. For nonincidental microcarcinomas, preoperative US features and cytological results were also available. mPTCc more often

showed a score \geq TR4 at ACR-TIRADS evaluation [10] or were categorized as high, according to the AACE/ACE-AME classification [11] ($P = .002$ for each). Notably, by ROC curve analysis, a high class of AACE/ACE-AME score showed a sensitivity of 82% and a specificity of 66% when identifying mPTCc (area under the curve [AUC]=0.671; 95% CI 0.56-0.78, $P = .004$) (Fig. 2A). An ACR-TIRADS score \geq TR4 was able to predict an mPTCc with a sensitivity of 79% and a specificity of 37% (AUC=0.670; 95% CI 0.55-0.79, $P = .004$) (Fig. 2B). Considering nonincidental tumors at presurgical cytology, Thy3/Tir3 was the main cytological result of mFVPTC, found in 56% of cases ($P < .001$), while Thy4/Tir4 and Thy5/Tir5 were found in 52% ($P = .037$) and 34% ($P = .004$) of the mPTCc, respectively (Table 3). When considering the histological features, only the infiltrative growth pattern showed a significant difference, being more prevalent in mPTCc ($P = .016$). Finally, about 72% of patients with nonincidental tumors were tested for *BRAF-V600E* and *RAS* mutations, with the former mutation more prevalent in mPTCc ($P < .001$) and the latter in mFVPTC ($P = .006$).

ATA Risk Classification According to Histological Variants

Regarding ATA risk stratification at diagnosis, all cases were distributed within the low- and the intermediate-risk classes, while no patients were classified as high risk. Table 4 shows a comparison between presurgical and postsurgical features of patients according to classic or follicular PTC histology and classified within the low- and intermediate-risk classes. Several significant differences were unveiled. Indeed, within the low-risk class, mFVPTC were older ($P = .004$), showed a lower rate of Thy4/Tir4 and Thy5/Tir5 cytology ($P < .001$), had lower scoring for US classifications ($P = 0.024$ and $P = .006$ for AACE/ACE-AME and ACR-TIRADS, respectively), had a smaller tumor size ($P = .005$), had a lower rate of infiltrative growth pattern ($P = .033$), and had a higher rate of *K-H-N-RAS* mutation ($P = .018$), resulting in a lower rate of *BRAF-V600E* mutation ($P = .008$). Considering the intermediate-risk class, only older age ($P = .003$), lower cytological results ($P = .023$), lower scoring with AACE/

Table 2. Population overview according to incidental or nonincidental diagnosis

	Incidental (n = 114)	Nonincidental (n = 121)	P
Age at diagnosis, years	58.8 ± 12.0	48.2 ± 14.6	<.001
TSH, mU/L	1.14 (0.33-1.78)	1.71 (0.99-2.7)	.001
mPTCc, n (%)	43 (37.7)	82 (67.8)	<.001
mFVPTC, n (%)	71 (62.3)	39 (32.2)	
Size, mm	3.0 ± 2.6	8.0 ± 2.1	<.001
Totally not capsuled, n (%)	87 (76.3)	71 (58.7)	.002
Multifocal, n (%)	28 (24.6)	59 (48.8)	<.001
Infiltrative growth, n (%)	37 (32.4)	55 (45.5)	.024
<i>BRAF-V600E</i> , ^a n (%)	12 (21.7)	57 (65.5)	<.001
<i>K-H-N-RAS</i> , ^a n (%)	10 (19.6)	7 (8.0)	.031
Minimal ETE, n (%)	7 (6.1)	51 (42.1)	<.001
N1, n (%)	2 (1.8)	26 (21.5)	<.001
ATA intermediate risk, n (%)	10 (8.8)	72 (59.5)	<.001

Abbreviations: ATA, American Thyroid Association; ETE, extrathyroidal extension; mFVPTC, follicular variant of papillary thyroid microcarcinoma; mPTCc, classical papillary thyroid microcarcinoma; NS, not significant; TSH, thyrotropin.

^aThe proportions refer to 133 molecular results from valid available tests.

Table 3. Population overview according to the histological variant in nonincidental microcarcinoma

	mPTCc (n = 82)	mFVPTC (n = 39)	P
Age at diagnosis, years	46.0 ± 14.4	54 ± 14.0	.015
TSH, mU/L	1.98 (1.15-3.21)	1.10 (0.82-2.26)	.007
AACE/ACE-AME high, n (%)	51 (62.2)	11 (28.2)	.002
ACR-TIRADS ≥ TR4, ^a n (%)	65 (79.3)	18 (46.1)	.002
Cytology (%)			
Thy3/Tir3, n (%)	11 (13.4)	22 (56.4)	<.001
Thy4/Tir4, n (%)	43 (52.4)	13 (33.3)	.037
Thy5/Tir5, n (%)	28 (34.1)	4 (10.3)	.004
Size, mm	8.2 ± 1.9	7.5 ± 2.3	.076
Not capsuled, n (%)	49 (59.7)	22 (56.4)	NS
Multifocal, n (%)	38 (46.9)	21 (53.8)	NS
Infiltrative growth, n (%)	43 (52.4)	12 (30.8)	.016
Minimal ETE, n (%)	38 (46.3)	13 (33.3)	NS
<i>BRAF-V600E</i> , ^b n (%)	45 (78.9)	12 (40.0)	<.001
<i>K-H-N-RAS</i> , ^b n (%)	1 (1.8)	6 (20.0)	.006
N1, n (%)	18 (22.0)	8 (20.5)	NS
ATA intermediate risk, n (%)	54 (65.9)	18 (46.2)	.031

Abbreviations: ACR-TIRADS, American College of Radiology Thyroid Imaging Reporting and Data Systems; ATA, American Thyroid Association; mFVPTC, follicular variant of papillary thyroid microcarcinoma; mPTCc, classical papillary thyroid microcarcinoma; NS, not significant; N1, positive lymph nodes; TSH, thyrotropin.

^aACR-TIRADS ≥ TR4 included all the thyroid nodules with a total score ≥ 4 points.

^bThe proportions refers to 133 molecular results from valid available tests.

ACE-AME classification ($P = .04$), and smaller tumor size ($P = .026$) were confirmed as significant for the mFVPTC subgroup. Interestingly, lower presurgical TSH values were also observed for mFVPTC ($P = .002$).

The incidental diagnosis was significantly more common for mFVPTC ($P = .013$) within the low-risk class, but this finding was not confirmed within the intermediate-risk class, where no difference was observed according to the histological results. This finding appeared to be a potentially relevant

point, requiring further analysis. Thus, in order to check for the independent effect of the histological variants (mFVPTC/mPTCc) and the incidental/nonincidental diagnosis a logistic regression model was constructed by entering the ATA risk class as the dependent variable and the above variables and age as covariates (Table 5). The results clearly indicate that both the histological variant (OR 0.465 [0.235-0.922]; $P = .028$) and the incidental/nonincidental diagnosis (OR 0.074 [0.034-0.163]; $P < .001$) of the tumor predicted stratification

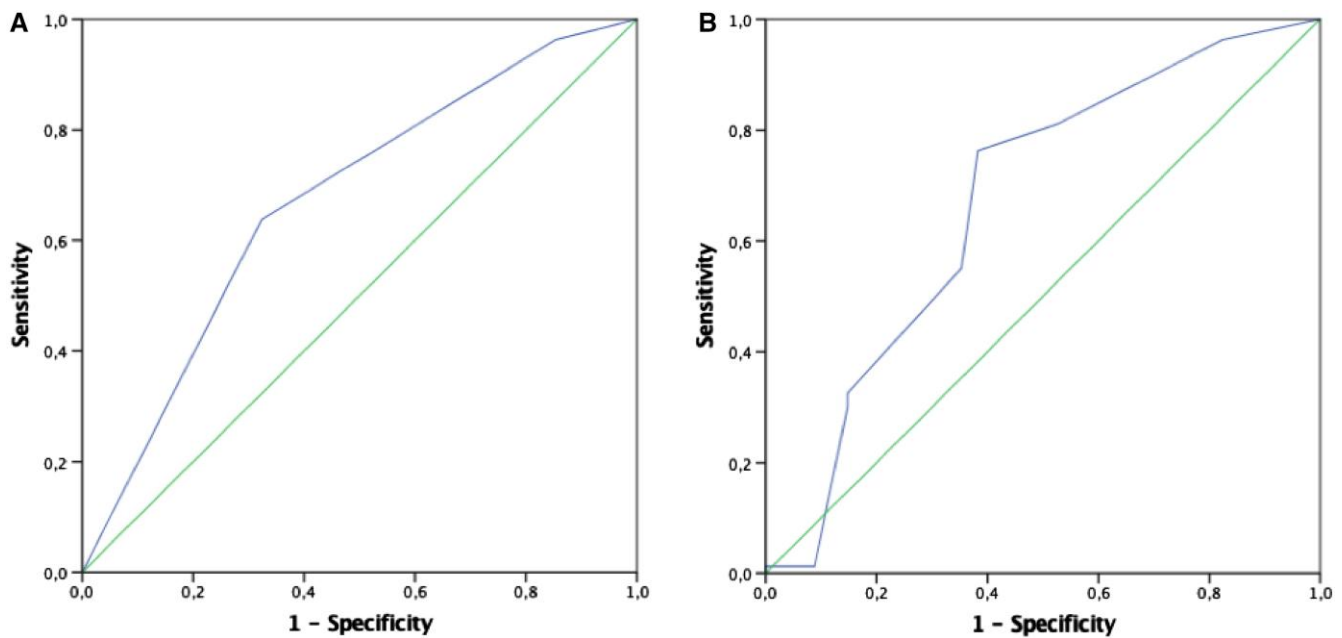


Figure 2. ROC curves plot of AACE/ACE-AME (A) and ACR-TIRADS (B) ultrasound score performance, according to mPTCc histology. (A) AUC of 0.671 (95% CI 0.561-0.781, $P = .004$); (B) AUC of 0.670 (95% CI 0.552-0.787, $P = .004$). Abbreviations: ROC, receiver operating characteristic; AACE/ACE-AME, American Association of Clinical Endocrinologists; ACR-TIRADS, American College of Radiology Thyroid Imaging Reporting and Data Systems; mPTCc, classical papillary thyroid microcarcinoma; AUC, area under the curve.

into the low- and intermediate-risk classes in a significant and independent manner. No age effect could be demonstrated (OR 1.004 [0.980-1.027]; $P = .768$).

Discussion

The present study provides a comprehensive insight into the presentation at diagnosis of mPTC, showing significant differences in tumor features, according to the 2 most frequent histological subtypes. mFVPTC appears as a separate disease, often discovered incidentally. In fact, incidental tumors and mFVPTC share several common clinical and histological features. Moreover, considering the ATA risk classification, mFVPTC was found to be significantly associated with a lower risk stratification, independently from other clinical and histological features and, more important, from incidental discovery. From this perspective, although thyroid microcarcinomas usually show an excellent prognosis, mFVPTC might represent a further marker of indolence.

Despite the advancement of knowledge on thyroid cancer biology, the therapeutic management of mPTC still puzzles physicians in clinical practice. This is especially true when addressing borderline situations, such as *larger* microcarcinomas [8, 9], or multifocal tumors [7], where the therapeutic strategy should be chosen balancing between the risk of overtreatment or undertreatment [7-9]. Incidental diagnoses are perceived with less suspicion, but, although considered as a separate entity, no further histological or clinical information has been fully and definitely associated with these tumors [2, 4]. For instance, at present, we found no study focusing on the histological variant and on the hypothetical relation with thyroid incidentalomas. Conversely, we often assume that the 2 major histological variants (ie, classical and follicular variants of PTC) occur likewise, underestimating some distinctive characteristics.

Among the findings of the present study, we observed that most of the incidental diagnoses were mFVPTC at histology, but the results of the multivariate analysis clearly indicated that both receiving an incidental diagnosis and a histologically proven mFVPTC identified those patients more prone to fall in the ATA low-risk class. In addition, when clinically discovered, mFVPTC showed more favorable presurgical features, at either cytology or US nodule classifications.

Among presurgical characteristics, we observed that elderly subjects more often showed favorable tumor features, such as smaller tumors and incidental occurrence. Despite the negative prognostic value of older age in thyroid cancer, some surveys show more favorable outcomes in elderly people within the mPTC field [8, 21]. In this regard, Ito et al suggested that older patients with low-risk PTC represented the ideal candidates for surveillance, due to the lower rate of disease progression [21]. The present results seem to be in line with the above, but further studies are required to investigate this finding.

Considering cytological results, most mFVPTCs showed Thy3/Tir3 cytology. It is well known that the follicular variant of PTC may determine false negative or indeterminate cytology, and in that event, the histological outcome is irrespective of nodule size [22]. Furthermore, Thy3/Tir3 cytology has already been associated with less aggressive tumors, appearing as a favorable prognostic factor [23]. On the other hand, US scores seem to be effective in assessing the risk of thyroid lesions, providing a valid stratification of mPTC behavior in our cohort according to the histological variant. In this regard, mFVPTC disclosed lower scoring than mPTCc using the ACR-TIRADS [11] and AACE/ACE-AME [12] classifications, showing milder US features more similar to follicular adenomas, as found in a previous study [24]. Milder US features for the follicular variant of PTC have also been evidenced with other methods of nodule scoring, such as the

Table 4. Comparison between pre-surgical and surgical features of classic and follicular variant of papillary thyroid microcarcinomas, within the same ATA risk class

	ATA low risk n = 153			ATA intermediate risk n = 82		
	mPTCc n = 66	mFVPTC n = 87	P	mPTCc n = 59	mFVPTC n = 23	P
Age, years	51.8 ± 15.5	58.3 ± 12.3	.004	46.8 ± 13.7	55.7 ± 13.4	.003
Male gender, n/n (%)	11/66 (16.7)	17/87 (19.5)	NS	13/59 (22.0)	4/23 (17.4)	NS
Thy/Tir ≥4 n/n (%)	24/30 (80.0)	6/30 (20.0)	<.001	47/58 (81.0)	11/58 (19.0)	.023
TSH at diagnosis, mU/L	1.5 (0.56-2.2)	1.1 (0.53-2.2)	NS	2.0 (1.4-3.6)	0.9 (0.2-1.2)	.002
AACE/ACE-AME ^a high, n/n (%)	18/23 (78.3)	5/23 (21.7)	.024	33/39 (84.6)	6/39 (15.4)	.040
ACR-TIRADS-TR, ^a ≥4 n/n (%)	23/30 (76.7)	7/30 (23.3)	.006	42/53 (79.2)	11/53 (20.8)	NS
Size, mm	5.3 ± 3.0	3.8 ± 3.2	.005	8.4 ± 1.7	7.1 ± 2.3	.026
Infiltrative growth pattern, n/n (%)	23/42 (54.8)	19/42 (45.2)	.033	37/50 (74.0)	13/50 (26.0)	NS
Not capsulated, n/n (%)	41/103 (39.8)	62/103 (60.2)	NS	38/55 (69.1)	17/55 (30.9)	NS
Multifocality, n/n (%)	15/37 (40.5)	22/37 (59.5)	NS	35/50 (70.0)	15/50 (30.0)	NS
Incidental, n/n (%)	38/104 (36.5)	66/104 (63.5)	.013	5/10 (50.0)	5/10 (50.0)	NS
<i>BRAF-V600E</i> , ^b n/n (%)	12/20 (60.0)	8/20 (40.0)	.008	38/49 (77.6)	11/49 (22.4)	NS
<i>K-H-N-RAS</i> , ^b n/n (%)	1/13 (7.7)	12/13 (92.3)	.018	2/4 (50.0)	2/4 (50.0)	NS

Bold numbers refer to statistically significant differences.

Abbreviations: ACR-TIRADS, American College of Radiology Thyroid Imaging Reporting and Data Systems; mFVPTC, follicular variant of papillary thyroid microcarcinoma; mPTCc, classical papillary thyroid microcarcinoma; TSH, thyrotropin.

^aAACE/ACE-AME and ACR-TIRADS classifications have been applied to all non-incidental tumors with available US information.

^bThe % has been considered on positive tests. The total number of valid tests was 133 for both ATA low-risk and ATA intermediate-risk subgroups.

Table 5. Age-adjusted logistic binary regression at diagnosis between incidental diagnosis and mFVPTC, considered as a dummy variable: 0 = low risk, 1 = intermediate risk

	Logistic binary regression OR (CI 95%)	P
Age	1.004 (0.980-1.027)	.768
Incidental diagnosis	0.074 (0.034-0.163)	<.001
mFVPTC	0.465 (0.235-0.922)	.028

Bold numbers refer to statistically significant differences.

Abbreviations: mFVPTC, follicular variant of papillary thyroid microcarcinoma; OR, odds ratio.

British Thyroid Association classification [25]. In line with the present study, Hughes et al confirmed that scoring was usually lower and lower cytological results for follicular variant of PTC compared with classical PTC [25]. However, follicular variant PTC with milder diagnostic features have mostly been associated with larger tumor size at histology, as opposed to cases having higher US scores or suspect/malignant cytological results [25, 26]. These last findings contradict our observations, where milder preoperative features were associated with smaller tumors. A possible explanation could be found in differences in the applied US scores and in the analyzed population sample [25, 26], since the present study only considered microcarcinomas, while other surveys included cases with any tumor size [25, 26].

The above statements are also in line with the results of molecular analysis, showing that mFVPTC, when either considering the whole sample or only the nonincidental cases, showed a lower rate of *BRAF-V600E* and a higher rate of *RAS* mutations, thus, once again, closer to the follicular adenoma profile

[24]. In particular, *BRAF* mutations were significantly more frequent in mPTCc, whereas a previous survey failed to find the same association, even though it compared a smaller population of mPTCc (n = 97) and mFVPTC (n = 11) [27].

On the whole, considering the follicular variant, evidence in the literature is scanty and divergent, becoming very scarce in the field of microcarcinomas. With regards to all PTCs without size limitations, we found studies supporting a better outcome for FVPTC than PTCc [28-34]. In contrast, older studies reported a higher incidence of lung metastasis and worse prognosis for this follicular variant [35, 36]. Considering only microcarcinomas, we found even fewer reports, with most of the analysis focused on histological features, without complementary molecular or clinical data.

The present results appear in line with those of a Chinese study [37] performed in 1041 patients with mPTC reporting smaller tumors and milder behavior for mFVPTC, concluding that this variant represents a favorable prognostic factor [37]. On the other hand, Singhal et al [38] analyzed a large sample of mPTCc and mFVPTC from the Surveillance, Epidemiology, and End Results (SEER) registry. At odds with our results, they reported that mFVPTC subgroups are characterized by a larger tumor size and by multifocality, but also by older age and by a lower rate of lymph node metastasis [38]. Finally, another survey [39] analyzed a small cohort of unifocal mFVPTC, also concluding that this tumor displayed relatively indolent behavior. However, despite the reliable source of information, none of the aforementioned studies [37-39] considered some clinical features, such as presurgical presentation, TSH values, or molecular results. More interestingly, the present study is the first to report an association between mFVPTC and incidental diagnosis. Even though from a different setting, our observation is consistent with most of the

few previous studies [37–39], leading to a reconsideration of mFVPTC as a type of favorable prognostic factor.

We should acknowledge some limitations of the present study: the single center and the retrospective design, along with the change of the histological classification and of the treatment indications may represent a potential bias in data interpretation. Furthermore, due to the absence of preoperative information on incidental cases, we could not exclude that the lower TSH levels of the patients with mFVPTC are due to the presence of hyperfunctioning nodules or mild hyperthyroidism. Finally, the lack of follow-up information prevents any conclusion concerning differences in terms of the persistence/recurrences rate of each tumor subtype. Thus, the milder behavior of mFVPTC, as suggested by the favorable presentation within the present cohort, needs to be validated in a larger sample and supported by long-term follow-up.

The present study offers a full glimpse of the diagnostic presentation of the 2 most frequent mPTC variants, considering preclinical, molecular, and histological features. To the best of our knowledge, this is the first study that observed a strong association between the follicular variant and the incidental detection of mPTC. However, if confirmed during long-term follow-up, the results of the present study suggest that mFVPTCs has the same milder features as nonincidental cases, and, in addition, lower US scoring and mostly intermediate cytology during diagnostic procedures were found.

Conclusions

In conclusion, mFVPTCs show some differences in clinical presentation compared with mPTC. Although thyroid microcarcinomas exhibit a benign course in most cases, the follicular variant seems to retain a significant number of favorable features, including a prevalent onset at incidental diagnosis. These findings are in line with previous evidences about FVPTC, often considered as a milder disease. If confirmed in long-term follow-up studies, the most conducive prognosis of mFVPTC will allow for a better stratification of patients eligible for different therapeutic strategies and follow-up.

Funding

This work has not received any financial support.

Conflicts of Interest

All the other authors have no conflicts of interest and nothing to disclose.

Data Availability

Restrictions apply to the availability of some or all data generated or analyzed during this study to preserve patient confidentiality. The corresponding author will on request detail the restrictions and any conditions under which access to some data may be provided.

References

1. La Vecchia C, Malvezzi M, Bosetti C, *et al.* Thyroid cancer mortality and incidence: a global overview. *Int J Cancer*. 2015;136(9):2187–2195.

2. 2015 American Thyroid Association Management Guidelines for Adult Patients with Thyroid Nodules and Differentiated Thyroid Cancer: The American Thyroid Association Guidelines Task Force on Thyroid Nodules and Differentiated Thyroid Cancer. Accessed May 11, 2022. <https://pubmed.ncbi.nlm.nih.gov/26462967/>
3. Thyroid Cancer—Cancer Stat Facts. Accessed May 11, 2022. <https://seer.cancer.gov/statfacts/html/thyro.html>
4. Provenzale MA, Fiore E, Ugolini C, *et al.* “Incidental” and “non-incidental” thyroid papillary microcarcinomas are two different entities. *Eur J Endocrinol*. 2016;174(6):813–820.
5. Tong M, Li S, Li Y, Li Y, Feng Y, Che Y. Efficacy and safety of radiofrequency, microwave and laser ablation for treating papillary thyroid microcarcinoma: a systematic review and meta-analysis. *Int J Hyperthermia*. 2019;36(1):1278–1286.
6. Molinaro E, Campopiano MC, Pieruzzi L, *et al.* Active surveillance in papillary thyroid microcarcinomas is feasible and safe: experience at a single Italian center. *J Clin Endocrinol Metab*. 2020;105(3):e172–e180.
7. Kim SK, Park I, Woo J-W, *et al.* Total thyroidectomy versus lobectomy in conventional papillary thyroid microcarcinoma: analysis of 8,676 patients at a single institution. *Surgery*. 2017;161(2):485–492.
8. Wang Y, Guan Q, Xiang J. Nomogram for predicting central lymph node metastasis in papillary thyroid microcarcinoma: a retrospective cohort study of 8668 patients. *Int J Surg*. 2018;55:98–102.
9. Wang X, Lei J, Wei T, Zhu J, Li Z. Clinicopathological characteristics and recurrence risk of papillary thyroid microcarcinoma in the elderly. *Cancer Manag Res*. 2019;11:2371–2377.
10. Sparano C, Verdiani V, Pupilli C, *et al.* Choosing the best algorithm among five thyroid nodule ultrasound scores: from performance to cytology sparing—a single-center retrospective study in a large cohort. *Eur Radiol*. 2021;31(8):5689–5698.
11. Tessler FN, Middleton WD, Grant EG, *et al.* ACR thyroid imaging, reporting and data system (TI-RADS): white paper of the ACR TI-RADS committee. *J Am Coll Radiol*. 2017;14(5):587–595.
12. Gharib H, Papini E, Garber JR, *et al.* American Association of Clinical Endocrinologists, American College of Endocrinology, and Associazione Medici Endocrinologi Medical Guidelines for Clinical Practice for the Diagnosis and Management of Thyroid Nodules—2016 Update. *Endocr Pract*. 2016;22(5):622–639.
13. British Thyroid Association, Royal College of Physicians. Guidelines for the management of thyroid cancer. In: Perros P, ed. *Report of the Thyroid Cancer Guidelines Update Group*. 2nd ed. Royal College of Physicians; 2007.
14. Pacini F, Basolo F, Bellantone R, *et al.* Italian Consensus on diagnosis and treatment of differentiated thyroid cancer: joint statements of six Italian societies. *J Endocrinol Invest*. 2018;41(7):849–876.
15. AJCC Cancer Staging Manual. Accessed May 11, 2022. <https://link.springer.com/book/9780387884400>
16. Amin MB, Edge S, Greene F, *et al.*, eds. *AJCC Cancer Staging Manual*. 8th ed. Springer International Publishing; 2017.
17. Gao J, Aksoy BA, Dogrusoz U, *et al.* Integrative analysis of complex cancer genomics and clinical profiles using the cBioPortal. *Sci Signal*. 2013;6(269):p11.
18. Cerami E, Gao J, Dogrusoz U, *et al.* The cBio cancer genomics portal: an open platform for exploring multidimensional cancer genomics data. *Cancer Discov*. 2012;2(5):401–404. doi:10.1158/2159-8290.CD-12-0095. Erratum in: *Cancer Discov*. 2012 Oct;2(10):960. PMID: 22588877; PMCID: PMC3956037.
19. Sparano C. Supplement to: classic and follicular variant of papillary thyroid microcarcinoma: two different phenotypes beyond tumour size. Dataset. *J Endocrine Soc*, 2022. Deposited October 7, 2022. Zenodo. Doi: 10.5281/zenodo.7156718
20. Sparano C, Moog S, Hadoux J, *et al.* Strategies for radioiodine treatment: What’s New. *Cancers (Basel)*. 2022;14(15):3800.
21. Ito Y, Miyauchi A, Kihara M, Higashiyama T, Kobayashi K, Miya A. Patient age is significantly related to the progression of papillary microcarcinoma of the thyroid under observation. *Thyroid*. 2014;24(1):27–34.

22. Mehanna R, Murphy M, McCarthy J, *et al.* False negatives in thyroid cytology: impact of large nodule size and follicular variant of papillary carcinoma. *Laryngoscope*. 2013;123(5):1305-1309.
23. Trimboli P, Bongiovanni M, Rossi F, *et al.* Differentiated thyroid cancer patients with a previous indeterminate (Thy 3) cytology have a better prognosis than those with suspicious or malignant FNAC reports. *Endocrine*. 2015;49(1):191-195.
24. Kim DS, Kim J, Na DG, *et al.* Sonographic features of follicular variant papillary thyroid carcinomas in comparison with conventional papillary thyroid carcinomas. *J Ultrasound Med*. 2009;28-(12):1685-1692.
25. Hughes NM, Nae A, Barry J, Fitzgerald B, Feeley L, Sheahan P. Sonographic differences between conventional and follicular variant papillary thyroid carcinoma. *Eur Arch Otorhinolaryngol*. 2017;274(7):2907-2913.
26. Chai YJ, Suh H, Yi JW, *et al.* Factors associated with the sensitivity of fine-needle aspiration cytology for the diagnosis of follicular variant papillary thyroid carcinoma. *Head Neck*. 2016;38(S1):E1467-E1471.
27. Lu H-Z, Qiu T, Ying J-M, Lyn N. Association between BRAFV600E mutation and the clinicopathological features of solitary papillary thyroid microcarcinoma. *Oncol Lett*. 2017;13(3):1595-1600.
28. Giani C, Torregrossa L, Piaggi P, *et al.* Outcome of classical (CVPTC) and follicular (FVPTC) variants of papillary thyroid cancer: 15 years of follow-up. *Endocrine*. 2020;68(3):607-616.
29. Tielens ET, Sherman SI, Hruban RH, Ladenson PW. Follicular variant of papillary thyroid carcinoma. A clinicopathologic study. *Cancer*. 1994;73(2):424-431.
30. Lang BH-H, Lo C-Y, Chan W-F, Lam AK-Y, Wan K-Y. Classical and follicular variant of papillary thyroid carcinoma: a comparative study on clinicopathologic features and long-term outcome. *World J Surg*. 2006;30(5):752-758.
31. Zidan J, Karen D, Stein M, Rosenblatt E, Basher W, Kuten A. Pure versus follicular variant of papillary thyroid carcinoma: clinical features, prognostic factors, treatment, and survival. *Cancer*. 2003;97(5):1181-1185.
32. Passler C, Prager G, Scheuba C, *et al.* Follicular variant of papillary thyroid carcinoma: a long-term follow-up. *Arch Surg*. 2003;138-(12):1362-1366.
33. Burningham AR, Krishnan J, Davidson BJ, Ringel MD, Burman KD. Papillary and follicular variant of papillary carcinoma of the thyroid: initial presentation and response to therapy. *Otolaryngol Head Neck Surg*. 2005;132(6):840-844.
34. Baloch ZW, Shafique K, Flanagan M, Livolsi VA. Encapsulated classic and follicular variants of papillary thyroid carcinoma: comparative clinicopathologic study. *Endocr Pract*. 2010;16(6):952-959.
35. Carcangiu ML, Zampi G, Pupi A, Castagnoli A, Rosai J. Papillary carcinoma of the thyroid. A clinicopathologic study of 241 cases treated at the University of Florence, Italy. *Cancer*. 1985;55(4):805-828.
36. Chang H-Y, Lin J-D, Chou S-C, Chao T-C, Hsueh C. Clinical presentations and outcomes of surgical treatment of follicular variant of the papillary thyroid carcinomas. *Jpn J Clin Oncol*. 2006;36-(11):688-693.
37. Zhi J, Zhao J, Gao M, *et al.* Impact of major different variants of papillary thyroid microcarcinoma on the clinicopathological characteristics: the study of 1041 cases. *Int J Clin Oncol*. 2018;23(1):59-65.
38. Singhal S, Sippel RS, Chen H, Schneider DF. Distinguishing classical papillary thyroid microcancers from follicular-variant microcancers. *J Surg Res*. 2014;190(1):151-156.
39. Xu B, Farhat N, Barletta JA, *et al.* Should subcentimeter non-invasive encapsulated, follicular variant of papillary thyroid carcinoma be included in the noninvasive follicular thyroid neoplasm with papillary-like nuclear features category? *Endocrine*. 2018;59(1):143-150.